

5 Tips for Success with Tutoplast Pericardium

A glaucoma surgeon shares pearls and pitfalls from her experience.

WHEN I BEGAN PERFORMING TUBE-shunt procedures, the eye-banked sclera I used to cover the shunt was not easily accessible. At Wills Eye Hospital, I was luckier than most, but not on every occasion, since successfully obtaining sclera from the eye bank was sporadic at best. Plus, like other ophthalmologists, I found that the sclera was not as good when frozen or preserved and that, despite the promise of sterility, there still were always concerns about AIDS transmission.

For these reasons, I began using IOP

Inc.'s Tutoplast processed pericardium as an alternative to eye-banked sclera. With a shelf life of five years, this allograft offered me the tremendous advantages of easy availability and total sterility—any time I needed to put in a tube shunt. Plus, the material often-times costs less than eye-banked sclera. I should mention that New World Medical Inc. makes processed pericardium, as well.

Of course, I could have gone with other options, such as fascia. Like eye-banked or

preserved sclera, though, fascia is difficult to obtain and of irregular thickness. Its response also varies, and it can be difficult

to sew down. Some ophthalmologists, like George Spaeth, MD, actually create a flap from the patient's own

sclera and fold it over as an autologous scleral graft. Not every patient, however, has adequately thick sclera or enough sclera overall for this alternative. Such a patient might be a high myope or someone with thin sclera who has had retinal surgery before or has a tremendous amount of scarring.

For me, Tutoplast pericardium has been the best option. In this article, I will share a few pearls and pitfalls from my experience that I hope will help you, should you also choose to use this allograft.

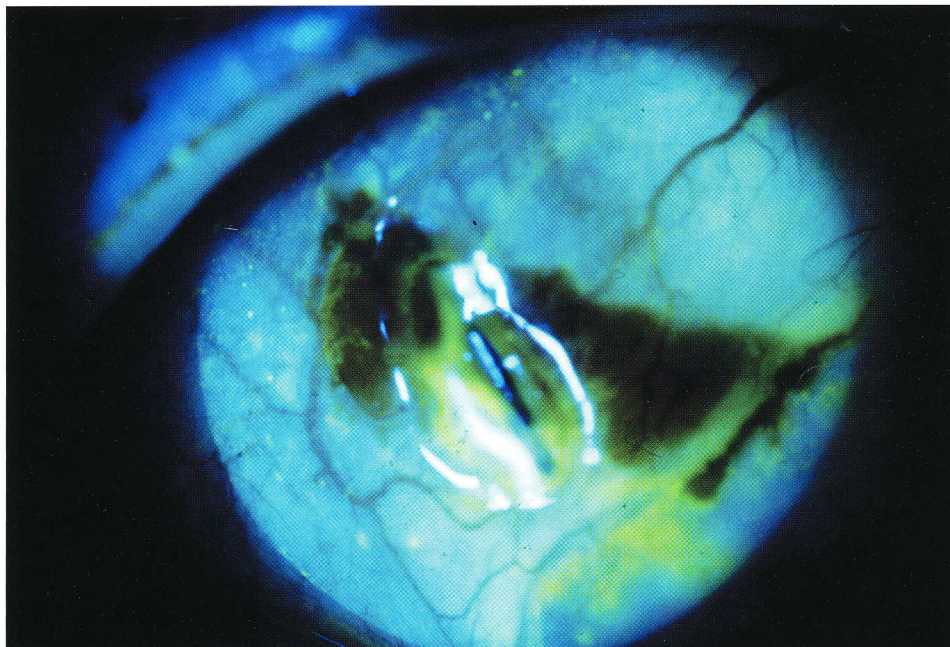
1. Opt for Double Thickness.

From 1996 to December 1998, I used single-thickness Tutoplast pericardium.

Figure 1. Double up the allograft.

Approximately 11 percent of the eyes in which I used single-thickness Tutoplast pericardium had erosion of the allograft, as seen above. Since January 1999, I have covered 48 tube shunts with double-thickness processed pericardium and have had no erosions to date.

Marlene R. Moster, MD
Philadelphia



Since it was supposed to be very strong and reliable, I figured that a thinner piece would be better than a fatter one, because it would avoid unsightly thickness and be better tolerated around the tube and on the eye.

After that, I began using double-thickness Tutoplast pericardium, a choice I strongly recommend to anyone working with the allograft.

I found, however, that six of 53 consecutive eyes (approximately 11 percent) had erosion of the allograft. Five of these

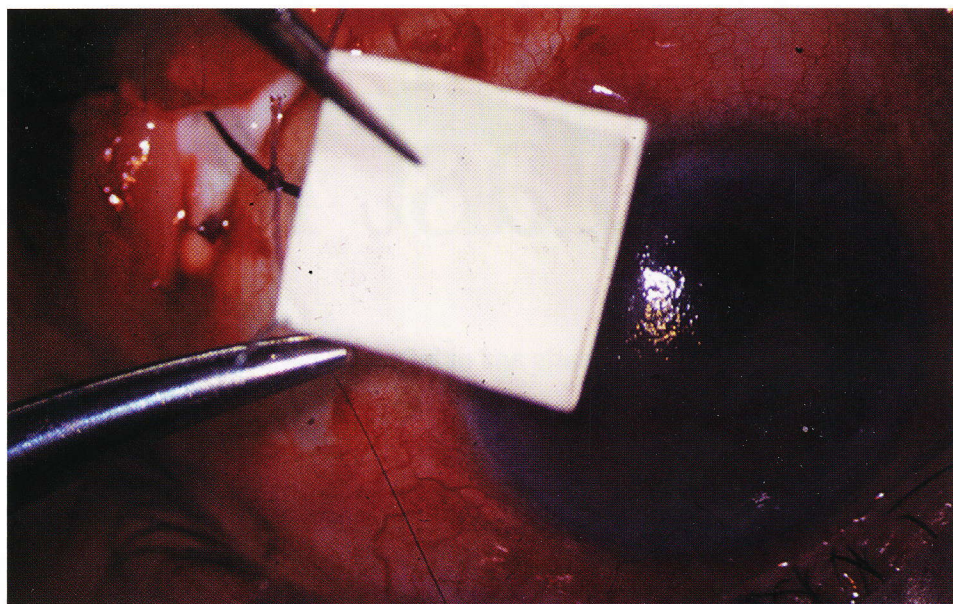


Figure 2. After cutting the allograft to the right dimensions, I fold it in half and take a bite with the 10-0 nylon in one corner, all while the material is dry and easy to handle.

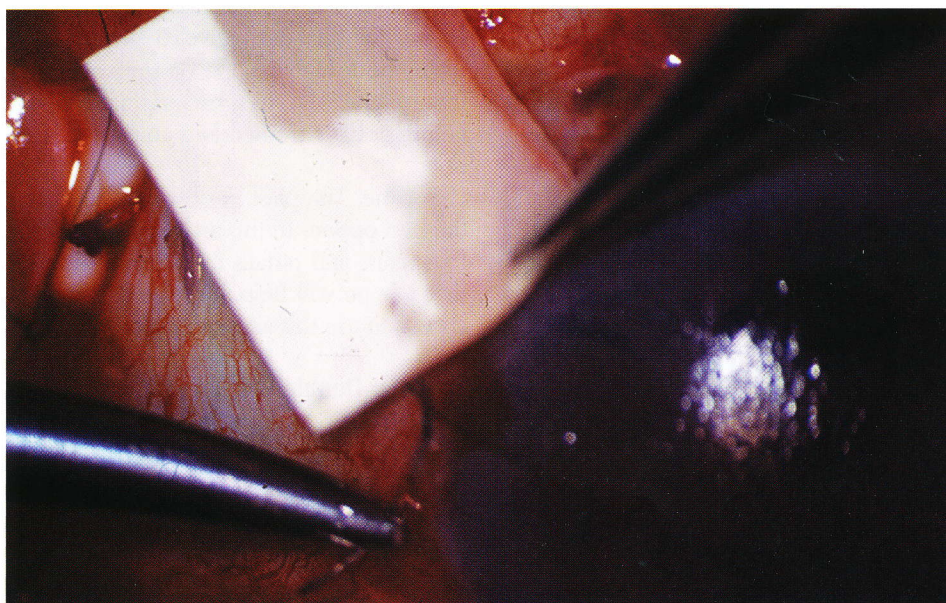


Figure 3. I then place the folded edge of the processed pericardium exactly at the limbus or slightly into clear cornea. The pre-placed suture allows me to secure one corner of the allograft right at the limbus by taking another bite with the nylon. Two or three additional sutures will securely cover the shunt.

patients had open-angle glaucoma and one neovascular glaucoma. The average time to erosion was 9.2 months. Upon review, we could not identify any predictive factors for erosion in the patients themselves. We found no direct relation between the incidence of erosion and diagnosis, patient health or prior surgery.

After that, I began using double-thickness Tutoplast pericardium, a choice I strongly recommend to anyone working with the allograft. Since January 1999, I have covered 48 tube shunts with double-thickness Tutoplast pericardium and have had no erosions to date. Moreover, because the pericardium is only 0.5-mm thick, it causes no unsightly bulkiness when doubled. The allograft's thickness is constant, unlike donor sclera, so there are no surprises.

2. Keep It Dry.

I find it easiest to cut the allograft while it is dry, when it resembles parchment. If you

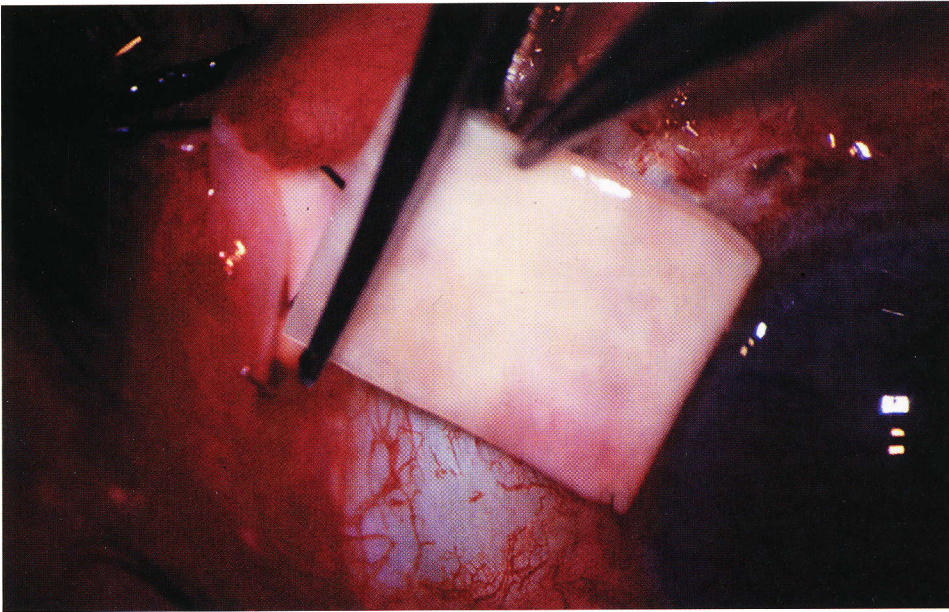


Figure 4. Cut the posterior part of the pericardium just anterior to where the tube actually inserts into the plate.

wet it first, you will find yourself struggling to cut accurate dimensions in something much like a wet tissue. I cut it vertically to the desired width.

3. Prepare the Site Carefully.

Prior to placing the allograft, I use a 67 blade or Weskott scissors to remove any redundant conjunctiva adjacent to the tube. I am careful to place the pericardial allograft directly on sclera so that the adhesion created will be solid.

4. Pre-place a Suture.

Once I have cut the Allograft to the right dimensions, I fold it in half and take a bite with the 10-0 nylon in one corner, while the allograft is still dry. Next, I place the Tutoplast pericardium on the eye with the folded side at the limbus. The eye itself wets the allograft.

It is important to place the edge of the pericardium exactly at the limbus or slightly into clear cornea, since it may retract with

Every effort should be made to avoid tube exposure.

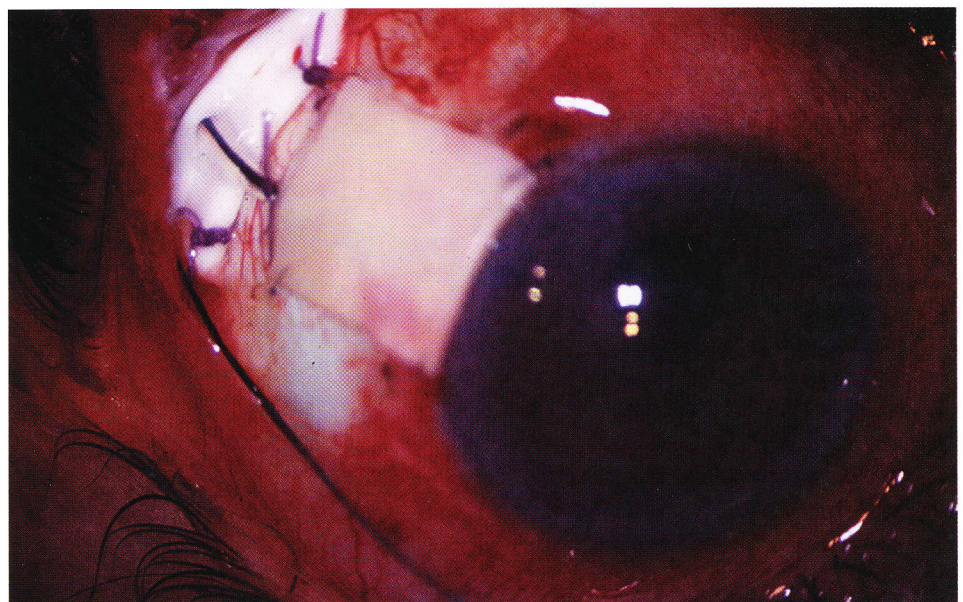


Figure 5. Because the processed pericardium is only 0.5-mm thick, doubling it does not result in unsightly bulkiness. I do not worry about surprises, because the allograft is of a constant thickness.

Glaucoma surgeons who would rather not double up their allograft may be interested in Tutoplast sclera from IOP Inc. The manufacturer processes this allograft similarly to its pericardial option, and it says that both products offer good durability and cosmesis.

According to the company, the recently released allograft is thicker and stiffer than Tutoplast processed pericardium, and its thickness varies as does that of natural sclera.

the conjunctiva. I find this to be the case especially with fornix-based conjunctival flaps. Every effort should be made to avoid tube exposure.

Since I have a pre-placed suture, I can then take another bite with the nylon right at the limbus, exactly where I want it. It tacks down beautifully. Often, when I place the allograft over the tube, I find it to be a touch too long or wide. As long as one corner is secure at the limbus, you'll easily be

able to trim the allograft to the exact size needed.


You will need two or three additional sutures in the corners in order to cover the tube shunt securely. If you're using a non-valved shunt, however, you can direct the flow and amount of leakage by adjusting the amount of sutures around the graft. For example, if I made too many slits with a sharp blade and the chamber tended to shallow, I can add more sutures to the Tutoplast pericardium covering the tube in order to increase the resistance to flow.

I will never forget one case during which the processed pericardium got onto the back of my scrub nurse's glove and then transferred to another obscure place within the sterile field.

Alternatively, if I want a low intraocular pressure, I may only tack down the allograft at the limbus with two sutures so that there is little resistance from the overlying Tutoplast pericardium prohibiting flow. In this manner, I can maximize the aqueous outflow from the slits.

A pre-placed suture will also help you to keep track of the cut allograft, which looks like a very small Band-aid. You can lose this tiny allograft in the blink of an eye—a costly mistake. I will never forget one case during which the processed pericardium got onto the back of my scrub nurse's glove and then transferred to another obscure place within the sterile field. It took a lot of looking to find it.

Be sure to cut the posterior part of the pericardium just anterior to where the tube actually inserts into the plate. The allograft should not cover this notch.

In a non-valved tube, like a Baervault, I use a ligature suture such as vicryl to tie it off. The allograft should end anterior to this suture so that the vicryl can dissolve in six to eight weeks. If the allograft covers the vicryl, it is less likely that the suture will open up at the predicted time. 

Dr. Moster is an attending surgeon on the Glaucoma Service at Wills Eye Hospital and is in private practice. She is also an associate professor of ophthalmology at Thomas Jefferson University.

5. Watch the Placement.